

## **Radiograph-Negative Lateral Ankle Injuries in Children Occult Growth Plate Fracture or Sprain?**

Kathy Boutis, MD, et al  
JAMA Pediatrics, January 2016

1. This is a well done paper to basically prospectively determine the incidence of plain film-negative lateral ankle x-rays in a study of injuries in children ages 5 -12 to ascertain the incidence of occult Salter-Harris type 1 fracture of the distal fibula ( SH1DF) vs soft tissue injuries vs neither. This was a fairly ambitious study where they obtained MRI scans prospectively on 135 children who had ankle injuries and negative plain films. Their main outcome measure was the proportion of such children with MRI-confirmed SH1DF. The results of this study showed that only 3% of these children had occult SH1DF: 108/135 had ligamentous injuries and 27/135 had bone contusions. The bottom line is that all categories as listed did well with full activity at 3 months. The conclusions of the paper are that Salter-Harris fractures of the distal fibula are rare in children with radiograph fracture-negative lateral ankle injuries. Furthermore, most of these children have ligamentous injuries and a few have occult avulsion fractures, but all do heal well.
2. The “at a glance” section on page 2/7 also gives a nice summary of the findings of this paper. The salient aspects of this paper again, are that only 3% of such patients had a SH1DF. A secondary and probably more important finding was that such children with fractures detectable only by MRI had similar recovery vs those with sprains when treated with a removable ankle brace and self-regulated return activities.
3. These findings are significantly important because historically, such patients were treated with casting and immobilization up to three months. The follow-up of these patients were excellent with orthopedic follow-up and telephone follow-up.
4. On page 4/7 the author’s reiterate that the functional recovery was the same whether patients had sprains, bone bruises, avulsion fractures, or SH1DF. I think one of the take home points is that we should treat such children with removable splints and activity as tolerated. We probably can refer all patients to their family doctors and pediatricians rather than orthopedic surgery. I believe this paper will change our everyday practice with such injuries.

## Original Investigation

# Radiograph-Negative Lateral Ankle Injuries in Children Occult Growth Plate Fracture or Sprain?

Kathy Boutis, MD, MSc; Amy Plint, MD, MSc; Jennifer Stimec, MD; Elka Miller, MD; Paul Babyn, MD; Suzanne Schuh, MD; Robert Brison, MD; Louis Lawton, MD; Unni G. Narayanan, MBBS, MSc

Editorial at  
jamapediatrics.com

**IMPORTANCE** Lateral ankle injuries without radiographic evidence of a fracture are a common pediatric injury. These children are often presumed to have a Salter-Harris type I fracture of the distal fibula (SH1DF) and managed with immobilization and orthopedic follow-up. However, previous small studies suggest that these injuries may represent ankle sprains rather than growth plate fractures.

**OBJECTIVES** To determine the frequency of SH1DF using magnetic resonance imaging (MRI) and compare the functional recovery of children with fractures identified by MRI vs those with isolated ligament injuries.

**DESIGN, SETTING, AND PARTICIPANTS** A prospective cohort study was conducted between September 2012 and August 2014 at 2 tertiary care pediatric emergency departments. We screened 271 skeletally immature children aged 5 to 12 years with a clinically suspected SH1DF; 170 were eligible and 140 consented to participate.

**INTERVENTIONS** Children underwent MRI of both ankles within 1 week of injury. Children were managed with a removable brace and allowed to return to activities as tolerated.

**MAIN OUTCOMES AND MEASURES** The proportion with MRI-confirmed SH1DF. A secondary outcome included the Activity Scale for Kids score at 1 month.

**RESULTS** Of the 135 children who underwent ankle MRI, 4 (3.0%; 95% CI, 0.1%-5.9%) demonstrated MRI-confirmed SH1DF, and 2 of these were partial growth plate injuries. Also, 108 children (80.0%) had ligament injuries and 27 (22.0%) had isolated bone contusions. Of the 108 ligament injuries, 73 (67.6%) were intermediate to high-grade injuries, 38 of which were associated with radiographically occult fibular avulsion fractures. At 1 month, the mean (SD) Activity Scale for Kids score of children with MRI-detected fibular fractures (82.0% [17.2%]) was not significantly different from those without fractures (85.8% [12.5%]) (mean difference, -3.8%; 95% CI, -1.7% to 9.2%).

**CONCLUSIONS AND RELEVANCE** Salter-Harris I fractures of the distal fibula are rare in children with radiograph fracture-negative lateral ankle injuries. These children most commonly have ligament injuries (sprains), sometimes associated with radiographically occult avulsion fractures. Children with fractures detectable only by MRI had a comparable recovery with those with sprains when treated with a removable ankle brace and self-regulated return to activities. This work has the potential to simplify the care of these common injuries, safely minimizing the inconveniences and costs of overtreatment.

**Author Affiliations:** Author affiliations are listed at the end of this article.

**Corresponding Author:** Kathy Boutis, MD, MSc, 555 University Ave, Toronto, ON M5G 1X8, Canada (kathy.boutis@sickkids.ca).

*JAMA Pediatr.* 2016;170(1):e154114. doi:10.1001/jamapediatrics.2015.4114

**P**ediatric ankle injuries result in more than 2 million emergency department (ED) visits in the United States and Canada annually.<sup>1</sup> They most commonly present in skeletally immature children after forced inversion of the ankle, leading to swelling and tenderness over the lateral aspect of the ankle, without radiographic evidence of a fracture.<sup>1-3</sup> In their landmark study on physeal injuries, Salter and Harris<sup>4</sup> reported that physeal cartilage is relatively weak compared with the adjacent ligaments attached to the bone. Consequently, when subjected to tension forces during an injury, growing children are more likely to sustain a fracture through the physis rather than to rupture the ligaments.<sup>4</sup> In keeping with the Salter-Harris classification,<sup>4,5</sup> pediatric ankle injuries associated with tenderness overlying the physis of the distal fibula that show no radiographic evidence of a fracture are labeled as undisplaced Salter-Harris type I physeal fractures of the distal fibula (SH1DF). The presumption that these ankle injuries are fractures often commits these children to weeks of immobilization, repeated radiographs, and follow-up in an orthopedic clinic.<sup>5-7</sup> This has been the cornerstone of the diagnosis and management of these injuries for more than 50 years.<sup>4-8</sup>

However, studies using magnetic resonance imaging (MRI) of children with these types of lateral ankle injuries have identified very few cases of SH1DF, while ligament injuries (sprains) were found to be very common.<sup>9-12</sup> Although this evidence challenges the adage that growing children “do not get sprains,”<sup>7</sup> these studies were limited by their small samples and/or enrollment of relatively older children, who might be less likely to incur physeal separation. Consequently, the belief that most of these children have an underlying physeal fracture remains entrenched among emergency medicine physicians, pediatricians, and orthopedic surgeons.<sup>13,14</sup> Therefore, a more accurate and robust understanding of the anatomic pathology associated with this common clinical picture is necessary to affect practice change and minimize potentially unnecessary rigid immobilization and routine orthopedic follow-up.

The main objective of this study was to determine the frequency of true SH1DF in children with radiograph fracture-negative lateral ankle injuries using MRI. We hypothesized that SH1DF fractures would be infrequent and most would demonstrate MRI findings consistent with an ankle sprain.<sup>9-11,15</sup> We also compared the functional recovery of children with fractures identified by MRI vs those with ligament injuries when children with these injuries were uniformly treated with removable brace and self-regulated return to activities.

## Methods

### Study Design and Setting

This was a prospective cohort study conducted at 2 urban, university-affiliated tertiary care children's hospitals from September 2012 to August 2014. Both hospitals (Hospital for Sick Children, Toronto, Ontario, Canada, and Children's Hospital of Eastern Ontario, Ottawa, Ontario, Canada) are members of Pediatric Emergency Research Canada.

### At a Glance

- It remains relatively unknown how often skeletally immature children with radiograph-negative lateral ankle injuries have a Salter-Harris I fracture of the distal fibula; nevertheless, in this clinical scenario, this fracture is often presumed and children are managed with weeks of immobilization and orthopedic follow-up.
- We determined the frequency of true distal fibular Salter-Harris I fractures in children who presented with radiograph-negative lateral ankle injuries using magnetic resonance imaging (MRI). We also compared the functional recovery of children with fractures identified by MRI vs those with isolated ligament injuries.
- We found that distal fibular Salter-Harris I fractures occurred in only 3% of children with radiograph fracture-negative lateral ankle injuries; instead, these children most commonly have ligament injuries (sprains).
- We also established that children with fractures detectable only by MRI had a comparable recovery vs those with sprains when treated with a removable ankle brace and self-regulated return to activities.
- The results of this study have the potential to simplify the care of these common injuries, safely minimizing the inconveniences and costs of overtreatment.

### Study Population

We enrolled children aged 5 to 12 years who presented to the study EDs with an isolated lateral ankle injury and were clinically presumed to have SH1DF. A clinically presumed SH1DF presented with all of the following criteria: (1) limited weight bearing, (2) tenderness and swelling over the lateral aspect of the distal fibula at the level of the physis, and (3) 3 radiographic views of the ankle demonstrating open physes and the absence of a fracture.<sup>5-8</sup> Excluded were children with injuries greater than 3 days old, preexisting musculoskeletal or coagulopathic disease, developmental delay, history of ankle fracture within 3 months, and families with an insurmountable language barrier and/or no telephone access. The study was approved by the human ethics review boards at the Hospital for Sick Children and the Children's Hospital of Eastern Ontario.

### Study Interventions

#### Emergency Department

Trained research assistants screened patients daily from 8 AM to 11 PM using the ED electronic tracking system and identified children who presented to the ED with an ankle injury. The research assistants then contacted on-call study-specific research staff who arrived on-site within 15 minutes and worked with the treating physician to finalize eligibility. The radiologist on duty was consulted on all potentially eligible cases to verify the presence of open physes and the absence of a fracture. Eligible families were then approached for written informed consent and patient assent, where applicable. For enrolled patients, the study case report form was completed by the physician and included patient demographics, mechanism of injury, and the following physical examination findings: specific location of soft-tissue swelling/tenderness, pain score (Bieri Faces Pain Scale, 0-6),<sup>16</sup> and ability to bear weight (none, partial with limping [1-5 steps], partial with limping >5

steps, or full with no pain). Families also completed the modified performance Activities Scale for Kids (ASKp), which included 38 questions targeting physical function in the week prior to the injury.<sup>17,18</sup> In keeping with current practice at participating institutions and supportive evidence,<sup>17</sup> enrolled patients were treated with a removable air-stirrup ankle brace as needed and instructions to return to activities as tolerated.

#### Magnetic Resonance Imaging

Within 7 days of the injury, eligible patients underwent an MRI of both the injured and uninjured ankles using a GE 1.5-T Sigma MRI system (Sigma HD) with a phased array extremity coil. The following sequences were obtained for the injured ankle: sagittal and coronal short tau inversion recovery, sagittal T1 weight, coronal and axial proton density fast spin echo, and axial T2 fast spin echo with fat suppression. The uninjured side was imaged using axial T2-fast spin echo/proton density sequences and coronal short tau inversion recovery sequence. The slice thickness was 3 mm.

#### Orthopedic and Telephone Follow-up

One month after the injury, prior to seeing the orthopedic surgeon, parents completed the ASKp and also reported their child's weight-bearing status and return to baseline activities (almost never, not very often, some of the time, most of the time, or almost all of the time). Patients were then examined by a staff orthopedic surgeon who was informed of MRI results and underwent a repeat set of ankle radiographs. At 3 months after injury, parents were telephoned by a research assistant (blinded to the MRI results) to assess status of weight bearing and return to baseline activities.

#### Image Review

All images were reviewed by the 3 study pediatric radiologists, 2 with expertise in pediatric musculoskeletal injuries. One of the study radiologists was external to both study sites. All 3 radiologists were blinded to specific diagnoses, original reports, and to each other's reports. Any discrepancies between the study radiologists were resolved by consensus agreement.

An MRI-confirmed SHIDF was diagnosed if any of the following were confirmed: fibular physis widening; displaced fibular physis; evidence of disruption of the periosteum adjacent to fibular physis, along with increased signal intensity on T2-weighted fat-suppressed images; or no associated fracture extending into the metaphysis, epiphysis, or other bony area.<sup>11,19</sup> A cortical fracture was identified in the presence of a distinct fracture line crossing the cortex and/or trabeculae.<sup>11</sup> Avulsion fractures were reported if a fragment of bone or cartilage at the site of the attachment of a ligament was separated from nearby bones. Bone contusions were reported as diffuse areas of low signal intensity in the marrow on T1-weighted images and high signal intensity on T2-weighted images without any associated fracture line. A ligament injury was considered present if there was increased signal on T2-weighted imaging with morphological changes and/or disruption of the ligament. Low-grade injuries were noted if there was swelling, thinning, thickening, and/or irregularity of the liga-

ment but no disruption; intermediate to high-grade tears also included partial or complete disruption of the ligament.<sup>20</sup>

#### Outcomes

Our primary outcome was the proportion of MRI-confirmed SHIDF in the study population. Magnetic resonance imaging is currently the gold standard imaging modality that distinguishes between SHIDF fractures, cortical fractures, avulsions, and ligament injuries.<sup>11,21-24</sup> We performed an MRI of the uninjured ankle as an internal control.

Secondary outcomes included the proportion of ankle injuries with MRI-documented ligament injuries, bone contusions, and/or cortical or avulsion fractures. Children were considered to have an intermediate to high-grade ligament injury if at least 1 ligament demonstrated this grade of ligament injury. At 1 month, we determined physical function by reporting the mean ASKp,<sup>18</sup> where a difference of 7% or greater on the ASKp from baseline represents a clinically meaningful change in physical function.<sup>25</sup> We also compared the ASKp at 1 month in those with and without MRI-evident fractures. Finally, the proportion of children reported to have full painless weight bearing and a return to activities "almost all of the time" at 1 and 3 months was determined.

#### Statistical Analyses

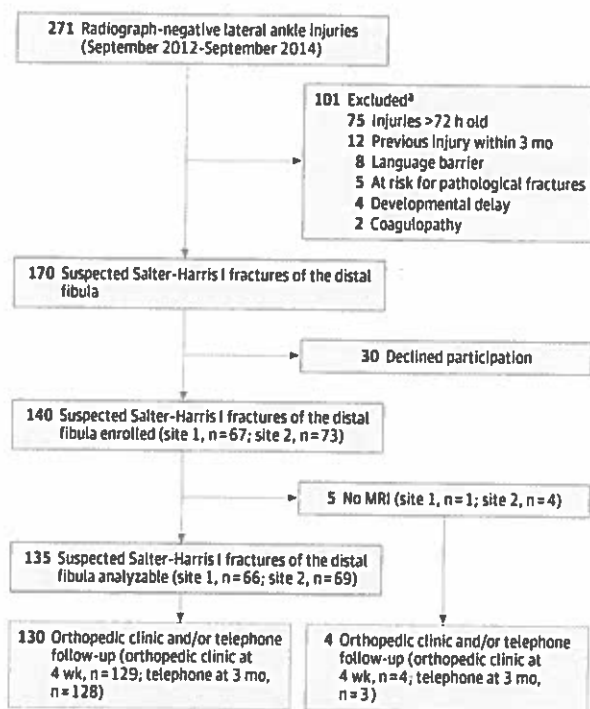
Previous relevant MRI and radiograph follow-up studies<sup>9-12,15,26</sup> identified a combined SHIDF incidence of 6% in clinically suspected cases. Research that included only MRI as the reference standard resulted in a combined SHIDF incidence of 3%.<sup>9-11,24,25</sup> Thus, assuming a sample proportion of 0.03 and a 2-sided 95% CI with a precision of  $\pm 0.03$  yielded a sample size of 125 patients (PASS version 11.0.7; NCSS). Assuming a 10% loss to follow-up necessitated enrollment of 140 patients.

Proportions were reported with respective 95% CIs and were compared using the Fisher exact test. Two means derived from parametric data were compared using the *t* test. Nonparametric continuous data from 3 or more independent groups were compared using the Kruskal-Wallis test. In the presence of small cell frequencies, exact methods were used to determine the level of significance for comparisons.<sup>27</sup> Significance was set at an  $\alpha < .05$ . All analyses were performed using SPSS for Windows (Version 20; IBM).

## Results

Of the 271 age-appropriate patients with radiograph-negative isolated ankle injuries who presented during the study at both sites, 170 met eligibility criteria, of whom 140 (82.4%) consented to participate (Figure 1). There were no differences in age ( $P = .91$ ) or sex ( $P = .62$ ) in those enrolled vs those who declined to participate. Of the 140 enrolled, 135 (96.4%) completed ankle MRI, 129 (95.6%) were evaluated at the 1-month orthopedic clinic visit, 116 (85.9%) had follow-up radiographs, and 128 families (94.8%) were successfully contacted at 3 months. The mean (SD) age of the enrolled patients was 9.2 (2.2) years, 90 (64.3%) were female, and there were no differences in baseline demographics between sites (Table 1).

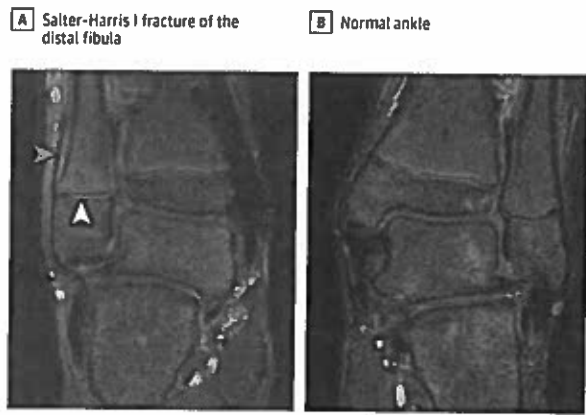
**Figure 1. Flowchart of Patients With a Suspected Salter-Harris Type I Fracture of the Distal Fibula**



Five patients were lost to follow-up.

\* The sum total is greater than 101 because some patients had multiple exclusion criteria.

**Figure 2. Salter-Harris Type I Fracture of the Distal Fibula**



A, Relative to the injured side, there is physeal widening and increased signal uptake in the growth plate (white arrowhead) and elevated periosteum by the subperiosteal hematoma extending proximally from the growth plate (blue arrowhead).

**Salter-Harris Type I Fracture of the Distal Fibula**

Of the 135 patients with MRI, 4 (3.0%; 95% CI, 0.1%-5.9%) demonstrated MRI evidence of SH1DF (Figure 2). Of these 4, 2 demonstrated abnormal signal through the entire growth plate and 2 involved injury to 25% to 50% of the length of

**Table 1. Patient Demographics and Clinical Characteristics of Ankle Injuries**

Variable	No. (%)	
	Site 1 (n = 67)	Site 2 (n = 73)
Age, mean (SD), y	9.6 (2.1)	8.7 (2.1)
Female	39 (58.2)	51 (69.9)
Preinjury Activities Scale for Klds score, mean (SD) <sup>a</sup>	93.2 (6.9)	91.8 (9.3)
Time from injury, mean (SD), h	20.7 (22.0)	21.4 (21.5)
Inversion mechanism	58 (86.6)	61 (83.6)
Swelling distal fibula	67 (100.0)	71 (97.3)
Tenderness distal fibula	66 (98.5)	72 (98.6)
Weight bearing		
None	21 (31.3)	22 (30.1)
Limping, 1-5 steps	28 (41.8)	28 (38.3)
Limping, >5 steps	18 (26.9)	23 (31.5)
Bieri Face Pain Scale score		
2	16 (23.9)	17 (23.3)
4	12 (17.9)	19 (26.0)
6	14 (20.9)	13 (17.8)
8	12 (17.9)	12 (16.4)
10	13 (19.4)	12 (16.4)

<sup>a</sup> Based on activities performed on week prior to the injury

the growth plate. All 4 had associated ligament injuries, 2 of which were intermediate to high-grade tears in the anterior talofibular ligament.

**Ligament and Other Bone Injuries**

Including the ligament injuries noted in the SH1DF cases, a total of 108 of 135 participants (80.0%) had ligament injuries. Of these 108, 73 children (67.6%) demonstrated at least 1 intermediate to high-grade ligament injury, while 33 (30.6%) demonstrated low-grade injuries exclusively. There were 38 distal fibular avulsion fractures identified only by MRI all associated with high-grade anterior-talofibular ligament tears. Bony contusions were evident in 107 of 135 cases (79.3%), 27 (20.0%) of which were the isolated finding.

**Functional Recovery**

The mean ASKp score at baseline prior to ankle injury was 92.3%, while at 1 month after injury, it was 83.4% (mean difference, -9.0%; 95% CI, -6.1% to -11.6%). At 1 month after injury 72.1% of participants (95% CI, 64.4%-79.8%) achieved full painless weight bearing, and by 3 months, this had increased to 96.1% (95% CI, 92.8%-99.5%). The percentage of children who had returned to normal activities "almost all of the time" at 1 and 3 months were 68.8% (95% CI, 60.8%-76.8%) and 96.9% (95% CI, 93.9%-99.9%), respectively. There was no difference in any of the measures of functional recovery between children with SH1DF, intermediate to high-grade ligament injuries, and those with low-grade ligament injuries at 1 and 3 months (Table 2). Furthermore, there was no difference in measures of functional recovery between those children with MRI-evident fibular fractures vs those without at these times after injury (Table 3).

**Table 2. Functional Recovery of Salter-Harris Type I Fractures of the Distal Fibula and Intermediate to High- and Low-Grade Ligament/Bone Contusion Injuries**

Variable	No. (%)			P Value
	Salter-Harris Type I Fracture of the Distal Fibula (n = 4)	Intermediate to High-Grade Ligament Injuries <sup>a</sup> (n = 71)	Low-Grade Ligament Injuries and/or Bone Contusion (n = 60)	
1-mo Follow-up	4	69	56	
Activity Scale for Kids score out of 100, mean (SD)	91.0 (6.8)	82.0 (15.3)	84.9 (15.5)	.57
Full weight bearing	4 (100)	49 (71.0)	42 (75.0)	.62
Return to activities "almost all of the time"	4 (100)	44 (63.8)	38 (66.0)	.39
3-mo Follow-up	4	68	56	
Full weight bearing	4 (100)	67 (98.5)	55 (98.2)	>.99
Return to activities "almost all of the time"	4 (100)	66 (97.0)	53 (94.6)	.71

<sup>a</sup> These include those ligament injuries with and without distal fibular avulsion fractures but without Salter-Harris type I fractures of the distal fibula.

**Table 3. Functional Recovery of Children With Fractures on MRI vs Those Without Fractures**

Variable	No. (%)		
	Fracture on MRI <sup>a</sup> (n = 42)	No Fracture on MRI (n = 93)	Difference (95% CI)
1-mo Follow-up	37	92	
Activity Scale for Kids, score out of 100, mean (SD), %	82.0 (17.2)	85.8 (12.5)	-3.8 (-1.7 to 9.2)
Full weight bearing	28 (75.7)	64 (69.6)	6.1 (-11.8 to 21.0)
Return to activities "almost all of the time"	26 (70.3)	60 (65.2)	5.1 (-13.3 to 21.0)
3-mo Follow-up	37	91	
Full weight bearing	37 (100)	86 (94.5)	5.5 (-4.4 to 12.2)
Return to activities "almost all of the time"	37 (100)	87 (95.6)	4.4 (-5.4 to 10.8)

Abbreviation: MRI, magnetic resonance imaging.

<sup>a</sup> Fractures include Salter-Harris type I fractures of the distal fibula and avulsion fractures.

### Enrolled Participants Without Magnetic Resonance Imaging

Five patients did not undergo MRI. Four of these with clinical follow-up at 1 month had a mean (SD) ASKp score of 81.5% (7.9%), 2 walked normally without pain, and 2 returned to baseline activities "almost all of the time." Of the 3 contacted at 3 months, all walked normally and had returned to baseline activities.

## Discussion

This study demonstrated that the commonly made presumptive diagnosis of SH1DF is rarely confirmed by MRI. These children most commonly have ligament injuries (sprains) occasionally associated with radiographically occult avulsion fractures. Children with fibular fractures detectable only by MRI had a comparable recovery vs those with lateral ankle sprains when treated with a removable ankle brace and self-regulated return to activities. Thus, in children with a clinical diagnosis of SH1DF, the concern about a possible occult fracture does not necessarily require a different treatment recommendation from that provided to children with ankle sprains.

Our results improve on the prior literature in several ways, more definitively demonstrating the very low frequency of SH1DF. Prior studies have had small sample sizes. Lohman et al<sup>11</sup> identified 6 children clinically classified as having SH1DF,

but all were proven to have ligament injuries on MRI. Our earlier study included 18 skeletally immature children with radiograph fracture-negative inversion injuries who underwent MRI, and 16 were found to have ligament injuries or bone contusions and 2 had other minor injuries.<sup>9</sup> There is a larger study by Launay et al<sup>10</sup> that included 116 children aged 8 to 15 years with any radiograph fracture-negative ankle injury. Thus, children did not specifically have the SH1DF clinical presentation and some had reached skeletal maturity. Keeping these limitations in mind, these authors also did not identify any SH1DF on MRI.<sup>10</sup> One small study provided contradictory results.<sup>12</sup> It included 10 children with radiograph-negative inversion injuries and found that 50% had MRI evidence of direct injury to the growth plate, with MRI interpretations from a single radiologist.<sup>12</sup> The strengths of our current study included an increased probability of capturing SH1DF by including younger children and specifying predefined clinical and MRI criteria with respect to the SH1DF diagnosis.<sup>5-8,11</sup> The MRI diagnosis was further validated by pediatric radiologists internal and external to study sites who specialize in musculoskeletal injuries and compared all findings with the internal control of the uninjured contralateral side. Importantly, we also sufficiently powered the study to determine the frequency of SH1DF based on prior estimates.<sup>9,12,15,26</sup> Thus, we can now be confident of the low frequency of confirmed SH1DF in skeletally immature children presenting with lateral ankle injuries without radiographic evidence of a fracture.

Our results have important management implications for skeletally immature children with radiograph fracture-negative lateral ankle injuries. Driven by a concern that children with this clinical picture likely have a physeal fracture, most pediatricians, emergency physicians, and pediatric orthopedic surgeons in North America manage these children with casting for 3 to 6 weeks.<sup>5,13,14</sup> However, our results strongly suggest that it is unnecessary to treat children who present with this common injury in a cast. This is supported by previous research that has shown that casting clinically suspected SH1DF may reduce the speed of recovery<sup>17,28,29</sup> and may increase health care costs.<sup>17</sup> The Choosing Wisely campaign has captured national attention in the United States and Canada in an effort to reduce unnecessary medical tests and treatments to enhance effective care choices and minimize the use of resources that do not positively influence clinical outcomes.<sup>30</sup> Based on this philosophy and our results, we advocate for a less-conservative approach focusing on a treatment strategy that minimizes patients' discomfort with a removable splint and allows for a return to activities as allowed by the patients' symptoms. Orthopedic consultation and radiographic follow-up are also not routinely necessary and should be reserved for patients who are not recovering as expected.

To our knowledge, this is the first study to quantify functional recovery timelines in a relatively large cohort of skeletally immature patients with MRI-defined ankle sprain injuries and treated with traditional sprain<sup>6</sup> management. At 1 month after the index ankle injury, children demonstrated a mean activity score in the range of a mild disability,<sup>25</sup> and about one-third of the children still reported mild restrictions in weight bearing and ability to fully return to usual activities 1 month after their injury. This contrasts with the findings of 2 randomized trials of removable brace vs cast for children with suspected SH1DF, which found that children in the brace group had activity scores at 4 weeks within the normal range.<sup>17,28</sup> However, these studies had smaller sample sizes and may not have been adequately powered to detect the effect of a higher number of intermediate to high-grade ligament injuries on

function. Nevertheless, nearly all children in this cohort were fully recovered by 3 months, regardless of the type of injury. Therefore, future research may examine the value and benefits of early intervention with physiotherapy on physical function within 1 month after the ankle injury.

Our results had some limitations. Our study did not consider the long-term outcome of growth arrest, a concern that may in part drive the aforementioned resource-heavy practice.<sup>5,8</sup> However, growth arrest in the setting of an isolated undisplaced SH1DF is exceedingly rare<sup>4</sup> and, to our knowledge, has not been reported in the literature. If it occurs, the damage is likely to be from the injury and unlikely to be reversed by the method of immobilization. The clinical significance of a growth arrest is further minimized because most longitudinal growth of the fibula occurs in the proximal fibular physis.<sup>4,5</sup> Finally, our results may apply less to clinicians who examine children infrequently because they may be more prone to error in their interpretation of physical examination findings and/or radiographs.

## Conclusions

In children with lateral ankle injuries who have no findings of a fracture on radiographs, the commonly made presumptive diagnosis of an SH1DF is seldom borne out by MRI. Most of these children have ankle sprain injuries, many of which are high-grade tears, undermining conventional wisdom about the relative weakness of the physeal cartilage compared with the adjacent ligaments. The most common fractures associated with this injury are minor avulsion fractures not picked up on radiographs. The specific structure injured, the ligament or bone, seems to have little bearing on the prognosis because children with or without MRI-evident fractures recovered comparably when treated with a removable brace and a self-regulated return to activities. This work has the potential to simplify the care of these common injuries, safely minimizing the inconveniences and costs of overtreatment.

### ARTICLE INFORMATION

**Accepted for Publication:** November 1, 2015.

**Published Online:** January 4, 2016.  
doi:10.1001/jamapediatrics.2015.4114.

**Author Affiliations:** Division of Emergency Medicine, Department of Pediatrics, the Hospital for Sick Children and the University of Toronto, Toronto, Ontario, Canada (Boutis, Schuh); Division of Emergency Medicine, Department of Pediatrics, Children's Hospital of Eastern Ontario and University of Ottawa, Ottawa, Ontario, Canada (Plint); Department of Diagnostic Imaging, The Hospital for Sick Children and University of Toronto, University of Toronto, Toronto, Ontario, Canada (Stimec); Department of Medical Imaging, Children's Hospital of Eastern Ontario and University of Ottawa, Ottawa, Ontario, Canada (Miller); Department of Radiology, University of Saskatchewan and Saskatoon Health Region, Saskatoon, Saskatchewan, Canada (Babyn); Department of Emergency Medicine, Kingston General Hospital and Queen's University, Kingston,

Ontario, Canada (Brisson); Division of Orthopaedic Surgery, Department of Surgery, Children's Hospital of Eastern Ontario and University of Ottawa, Ottawa, Ontario, Canada (Lawton); Division of Orthopaedic Surgery, Department of Surgery, The Hospital for Sick Children and University of Toronto, Toronto, Ontario, Canada (Narayanan).

**Author Contributions:** Dr Boutis had full access to all of the data in the study and takes responsibility for the integrity of the data and the accuracy of the data analysis. All authors read and approved the final manuscript.

**Study concept and design:** Boutis, Plint, Stimec, Miller, Babyn, Schuh, Brisson, Narayanan.  
**Acquisition, analysis, or interpretation of data:** Boutis, Plint, Stimec, Miller, Babyn, Schuh, Lawton, Narayanan.  
**Drafting of the manuscript:** Boutis, Babyn, Schuh, Narayanan.  
**Critical revision of the manuscript for important intellectual content:** All authors.  
**Statistical analysis:** Boutis, Narayanan.

**Obtained funding:** Boutis, Miller, Schuh, Brisson, Narayanan.

**Administrative, technical, or material support:** Boutis, Stimec, Miller, Babyn.

**Study supervision:** Boutis, Miller, Narayanan.

**Conflict of Interest Disclosures:** None reported.

**Funding/Support:** The operations of this study were funded by the Physician Services Incorporated granting agency (No. 12.04). DJO Global provided the Air-stirrup ankle brace used in this study.

**Role of the Funder/Sponsor:** The funding organizations had no role in the design and conduct of the study; collection, management, analysis, and interpretation of the data; preparation, review, or approval of the manuscript; and decision to submit the manuscript for publication.

**Additional Contributions:** We acknowledge the contributions of Dale Dalgleish, RN (Children's Hospital of Eastern Ontario), and Melissa Ouyang, RN (Hospital for Sick Children), in coordinating operations at each site. Further, the magnetic

resonance imaging technologists Ruth Weiss, MRT(MR)(R) and Tammy Rayner, MRT(MR)(R) (Hospital for Sick Children), and Barry Smith, MRT (MR) (Children's Hospital of Eastern Ontario), who ensured that enrolled participants completed their magnetic resonance imaging. We also thank research assistants who work as a part of the following research assistant programs: Pediatric Research Academic Initiative at SickKids Emergency (Hospital for Sick Children) and the Students Undertaking a Pediatric Program of Research Training (Children's Hospital of Eastern Ontario). We acknowledge the efforts of Cassandra Kapoor, BSc, CCRP (Children's Hospital of Eastern Ontario), as a research assistant and Kevin Tran, NRP (Hospital for Sick Children), who worked on data organization and data entry. Finally, we thank Andrew Willan, PhD (Hospital for Sick Children), for his review of the statistical analyses and corresponding results presented in the paper. Ms Dalglish and Ms Ouyang received compensation from the grant sponsor.

## REFERENCES

- Boutis K, Grootendorst P, Willan A, et al. Effect of the Low Risk Ankle Rule on the frequency of radiography in children with ankle injuries. *CMAJ*. 2013;185(15):E731-E738.
- Boutis K, Komar L, Jaramillo D, et al. Sensitivity of a clinical examination to predict need for radiography in children with ankle injuries: a prospective study. *Lancet*. 2001;358(9299):2118-2121.
- Gravel J, Hedrei P, Grimard G, Gouin S. Prospective validation and head-to-head comparison of 3 ankle rules in a pediatric population. *Ann Emerg Med*. 2009;54(4):534-540.e1.
- Salter RB, Harris WR. Injuries involving the epiphyseal plate. *J Bone Joint Surg*. 1963;45-A:587-622.
- Cummings RJ. Distal tibial and fibular fractures. In: Beaty JH, Kasser JR, Flynn JM, Skaggs DL, Waters PM, eds. *Rockwood and Wilkins' Fractures in Children*. 7th ed. Philadelphia, PA: Lippincott Williams and Wilkins; 2014:968-1038.
- Halstead ME. Pediatric ankle sprains and their imitators. *Pediatr Ann*. 2014;43(12):e291-e296.
- Marsh JS, Daigneault JP. Ankle injuries in the pediatric population. *Curr Opin Pediatr*. 2000;12(1):52-60.
- Podeszwa DA, Mubarak SJ. Physeal fractures of the distal tibia and fibula (Salter-Harris type I, II, III, and IV fractures). *J Pediatr Orthop*. 2012;32(suppl 1):S62-S68.
- Boutis K, Narayanan U, Dong FF, et al. Magnetic resonance imaging of the Salter-Harris I fracture of the distal fibula. *Injury*. 2010;41:852-856.
- Launay F, Barrau K, Petit P, Jouve JL, Auquier P, Bollini G. Ankle injuries without fracture in children: prospective study with magnetic resonance in 116 patients [in French]. *Rev Chir Orthop Reparatrice Appar Mot*. 2008;94(5):427-433.
- Lohman M, Kivisaari A, Kallio P, Puntilla J, Vehmas T, Kivisaari L. Acute paediatric ankle trauma: MRI versus plain radiography. *Skeletal Radiol*. 2001;30(9):504-511.
- Stuart J, Boyd R, Derbyshire S, Wilson B, Phillips B. Magnetic resonance assessment of inversion ankle injuries in children. *Injury*. 1998;29(1):29-30.
- Boutis K, Howard A, Constantine E, Cuomo A, Narayanan U. Evidence into practice: emergency physician management of common pediatric fractures. *Pediatr Emerg Care*. 2014;30(7):462-468.
- Boutis K, Howard A, Constantine E, Cuomo A, Somji F, Narayanan U. Evidence to practice: orthopedic management of common pediatric fractures. *J Pediatr Orthop*. 2015;35(1):18-23.
- Sankar WN, Chen J, Kay RM, Skaggs DL. Incidence of occult fracture in children with acute ankle injuries. *J Pediatr Orthop*. 2008;28(5):500-501.
- Bieri D, Reeve RA, Champion GD, Addicoat L, Ziegler JB. The Faces Pain Scale for the self-assessment of the severity of pain experienced by children: development, initial validation, and preliminary investigation for ratio scale properties. *Pain*. 1990;41(2):139-150.
- Boutis K, Willan AR, Babyn P, Narayanan UG, Alman B, Schuh S. A randomized, controlled trial of a removable brace versus casting in children with low-risk ankle fractures. *Pediatrics*. 2007;119(6):e1256-e1263.
- Young NL, Williams JJ, Yoshida KK, Wright JG. Measurement properties of the activities scale for kids. *J Clin Epidemiol*. 2000;53(2):125-137.
- Shi DP, Zhu SC, Li Y, Zheng J. Epiphyseal and physeal injury: comparison of conventional radiography and magnetic resonance imaging. *Clin Imaging*. 2009;33(5):379-383.
- Cheung Y, Rosenberg ZS. MR imaging of ligamentous abnormalities of the ankle and foot. *Magn Reson Imaging Clin N Am*. 2001;9(3):507-531. x.
- Jaramillo D, Hoffer FA. Cartilaginous epiphysis and growth plate: normal and abnormal MR imaging findings. *AJR Am J Roentgenol*. 1992;158(5):1105-1110.
- Jaramillo D, Hoffer FA, Shapiro F, Rand F. MR imaging of fractures of the growth plate. *AJR Am J Roentgenol*. 1990;155(6):1261-1265.
- Jaramillo D, Kammen BF, Shapiro F. Cartilaginous path of physeal fracture-separations: evaluation with MR imaging: an experimental study with histologic correlation in rabbits. *Radiology*. 2000;215(2):504-511.
- Jaramillo D, Shapiro F, Hoffer FA, et al. Posttraumatic growth-plate abnormalities: MR imaging of bony-bridge formation in rabbits. *Radiology*. 1990;175(3):767-773.
- Plint AC, Gaboury I, Owen J, Young NL. Activities Scale for Kids: an analysis of normals. *J Pediatr Orthop*. 2003;23(6):788-790.
- Gufler H, Schulze CG, Wagner S, Baumbach L. MRI for occult physeal fracture detection in children and adolescents. *Acta Radiol*. 2013;54(4):467-472.
- Agresti A. A survey of exact inference for contingency tables. *Stat Sci*. 1992;7(1):131-153. doi:10.1214/ss/1177011454.
- Barnett PL, Lee MH, Oh L, Cull G, Babl F. Functional outcome after air-stirrup ankle brace or fiberglass backslab for pediatric low-risk ankle fractures: a randomized observer-blinded controlled trial. *Pediatr Emerg Care*. 2012;28(8):745-749.
- Gleeson AP, Stuart MJ, Wilson B, Phillips B. Ultrasound assessment and conservative management of inversion injuries of the ankle in children: plaster of Paris versus Tubigrip. *J Bone Joint Surg Br*. 1996;78(3):484-487.
- ABIM Foundation. Choosing Wisely. <http://www.choosingwisely.org/>. Accessed June 15, 2015.